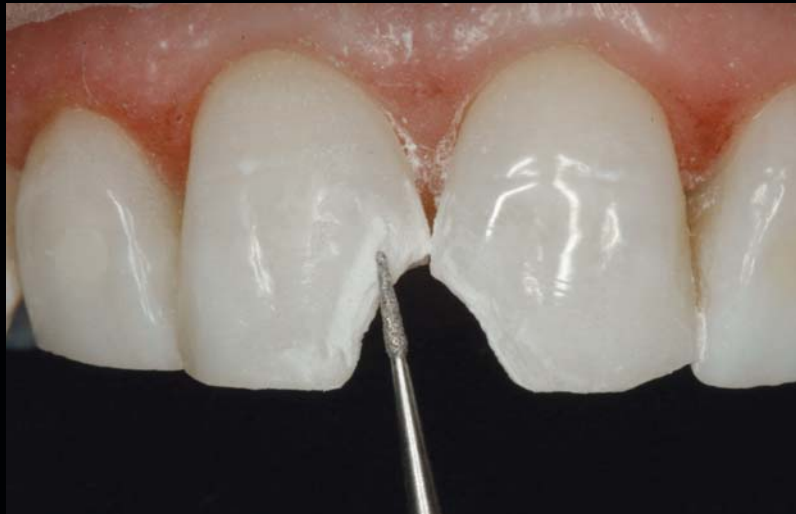

# CREATING TRANSLUCENT EDGE EFFECTS AND MAVERICK INTERNAL TINTS USING MICROHYBRID RESIN

Jeff T. Blank, DMD, PA



*Today's composite resins possess optical and physical characteristics that have expanded their clinical indications. The successful and predictable application of these materials depends on the practitioner's understanding of their material properties as well as the clinical requirements involved in their delivery; identifying the characteristics of the natural tooth is also important. This presentation reviews contemporary resin materials and demonstrates simple and repeatable guidelines for margin and material placement that improve the clinician's ability to implement microhybrid resins in daily practice.*

#### Learning Objectives:

This article discusses the use of a microhybrid resin to match the natural dentition in cases requiring a highly aesthetic restoration. Upon reading this article, the reader should:

- Understand an effective procedure clinicians can follow for providing realistic Class IV restorations.
- Realize the significant benefits that can be gained by using a bevel design.

*Key Words: composite, resin, edge effects, tints, bonding*

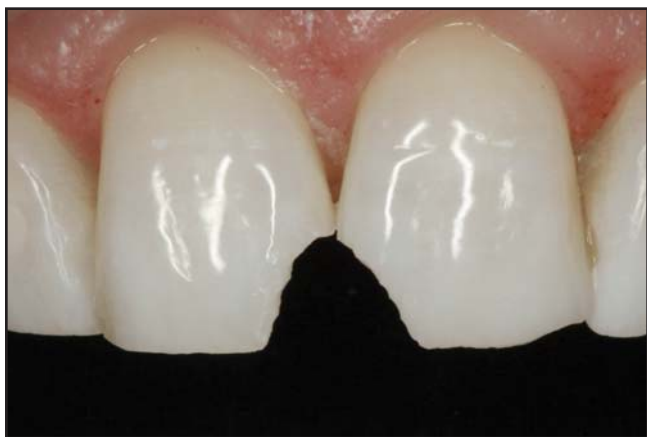---

*\*Private practice, Rock Hill, SC.*

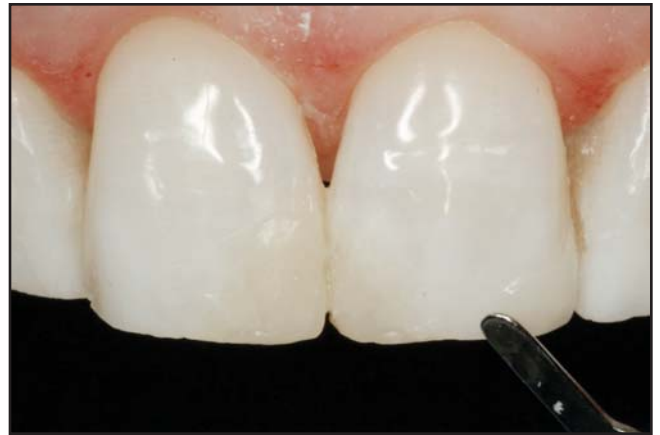**Jeff T. Blank, DMD, PA, 1318 Ebenezer Road, Rock Hill, SC 29732**  
Tel: 803-327-3240 • E-mail: [jblank@comporium.net](mailto:jblank@comporium.net)

The use of composite resin bonding in aesthetic dentistry has been well documented for years.<sup>1-3</sup> Providing clinicians with a conservative means of restoring the natural dentition or enhancing a patient's aesthetics, composite resins have grown in popularity since their introduction to dentistry decades ago. Although direct bonding techniques have been well documented in the literature, clinicians are sometimes reluctant to use them in indications where aesthetics are paramount (eg, Class IV fractures, diastema closure, direct resin veneers). In these situations, indirect restorations can be more predictable than the freehand bonding of even contemporary resin formulations.

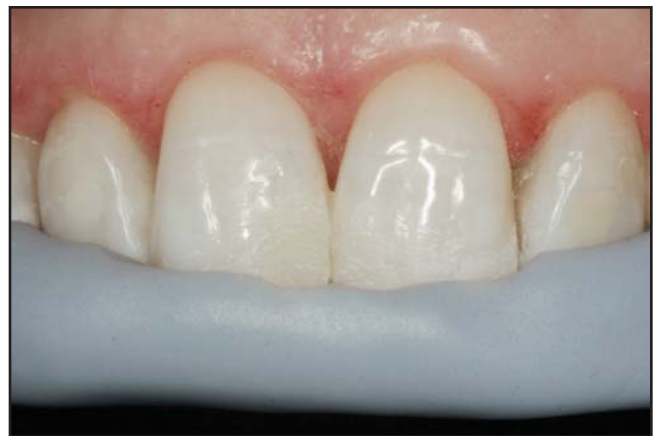Early techniques for resin bonding involved the layering of hybrid and microfill materials to achieve the strength and aesthetics, respectively, witnessed in the natural dentition.<sup>4,5</sup> The handling characteristics, polishability, and shade compatibility of hybrid and microfill resins, however, differed from one another and required the clinician to have a thorough understanding of the indications for each in order to use them successfully in combination. Most recently, microhybrid resins (eg, Venus, Heraeus Kulzer, Armonk, NY; Premise, Kerr/Sybron, Orange, CA; Tetric EvoCeram, Ivoclar Vivadent, Amherst, NY) have been developed in an effort to provide practitioners with a single material that could be applied universally in posterior and anterior regions of the mouth.<sup>6,8</sup> The author uses Venus (Heraeus Kulzer, Armonk, NY) for its shade-matching capabilities and its ability to be easily contoured using various brushes and composite resin instruments.



**Figure 1.** Preoperative facial view of the maxillary central incisors with trauma along the mesial-incisal edges.



**Figure 2.** A mockup was created to serve as a model and to verify the occlusion.

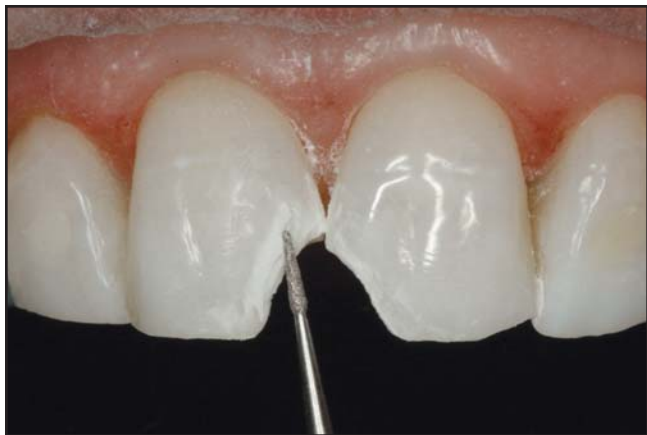

**Figure 3.** The utilization of a silicone index permits swift build up of the restoration against a supporting scaffold.

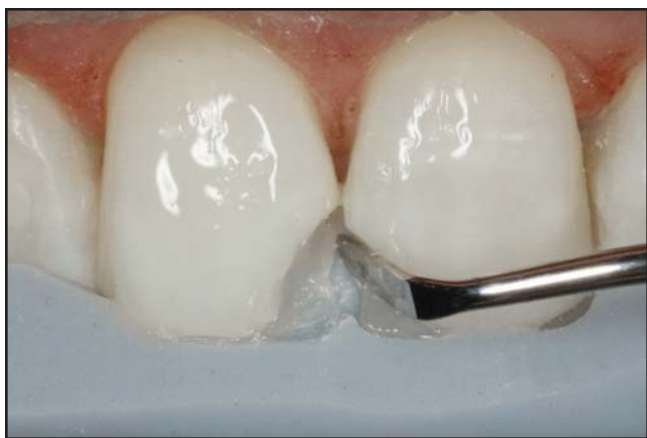Using a detailed case presentation, this article demonstrates the layered application of a microhybrid resin and various tints to replicate the natural dentition in a patient with two Class IV fractures.

### Preparation Requirements

Principally, the Class IV restoration requires the clinician to design a preparation that will enable the resin to be seamlessly integrated with the remaining tooth structure.<sup>9</sup> Additionally, the tooth preparation must create sufficient space to enable the buildup of multiple layers and opacities of composite resin. Preparation of a long but uneven bevel on the facial aspect allows for a sufficient, natural-looking transition of the restoration to the remaining



**Figure 4.** A 4-mm to 6-mm bevel was created to yield a realistic, seamless transition. This technique allows the margin to be camouflaged.



**Figure 5.** A translucent base layer resin was built up against the silicone index to create the adhesive surface on which subsequent layers would be applied.

dentition and conceals the margin.<sup>10</sup> A bevel design can also offer greater fracture resistance and retention in that it increases the total bonding surface area and allows more restorative material to be utilized.<sup>11</sup> Additionally, a design should be followed that tapers cervically from its widest point incisally.<sup>12</sup>

As this in and of itself is not an innovative concept, why do many clinicians fail to achieve the intended outcome when following these simple guidelines? In the author's experience, it is the reproduction of translucent edge effects and maverick internal tints that enable accurate recreation of the natural dentition. Thus, it is this process that must be implemented as described in the following case presentation when ideal aesthetics are desired.

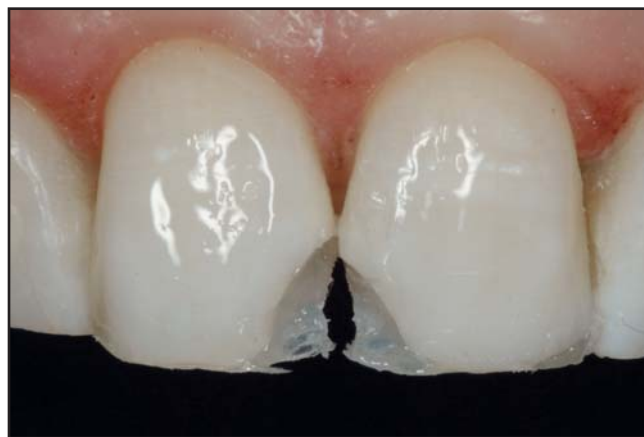### Case Presentation

A 45-year-old female presented after trauma that had fractured the mesial-incisal edges of teeth #8(11) and #9(21) (Figure 1). A clinical examination was completed, and several options—ranging from indirect porcelain restorations to direct resins—were presented to the patient. As direct resin restorations would represent an immediate and conservative treatment option for the Class IV fractures, the patient opted to proceed accordingly.

### Clinical Protocol

Due to the trauma to the patient's lips and gingival tissues, the free gingival margins of teeth #8 and #9 were hyperemic; an aluminum chloride gel (ie, Viscostat, Ultradent Products, South Jordan, UT) was used to chemically cauterize the tissues and to achieve a more viable working field. Prior to initiating care, digital photographs were taken; the images were displayed on a computer monitor. This enabled the author to assess the general shade, translucency, and maverick colors in the remaining healthy tooth structure. These characterizations would need to be replicated in the direct resin restorations. While minimal translucency was noted, the inclusion of vertical white hypocalcified internal tints were identified.

A freehand mockup of the restorations was created using composite resin.<sup>7</sup> The primary objective of the mockup was to establish the lingual anatomy congruent with the patient's occlusion in centric occlusion as well as protrusive and eccentric movements. When stratifying restorations, determining the exact thickness of each layer can be difficult, and if occlusion had not been verified



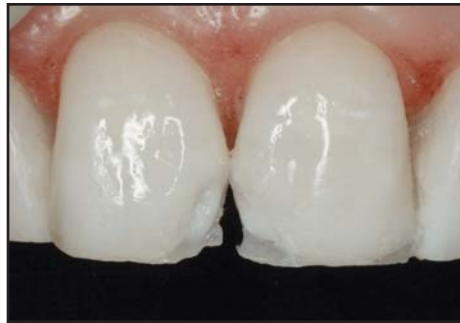**Figure 6.** The small layer of composite is light cured and the silicone index is removed.

prior to resin layering, much of the effort could have been destroyed when the occlusion was adjusted after the completion of the restorations. Other key parameters included in the mockup were the facial embrasures and final incisal edge position (based on tripodization in edge-to-edge protrusion) (Figure 2). This mockup would enable the fabrication of a lingual-incisal silicone index that would permit the rapid buildup of the stratified restorations (Figure 3).

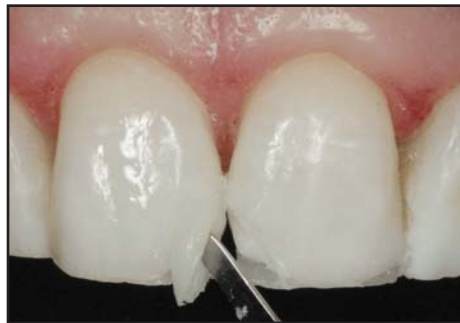Preparation of the Class IV fracture involved minimal tooth reduction to simply remove unsupported enamel and dentin, and create the rounded internal line angles that would better facilitate adaptation of the microhybrid resin layers. Proper beveling of the enamel, particularly on the facial aspect, was critical. The author thus established a large (ie, 4 mm to 6 mm) undulating bevel with a course, flamed-shaped diamond bur (Figure 4). Such an extensive bevel would allow room for the transition of the final translucent enamel shade into the natural tooth structure for a seamless restoration.

Layering begins with the placement of a translucent lingual “shelf” that served as scaffolding on which further shades and opacities were built. To create the shelf, the silicone index was lubricated with a resin modeling agent (ie, Compo-Connect, Heraeus Kulzer, Armonk, NY), which helps the resin wet and adapt to the silicone index. Both teeth were acid-etched for 15 seconds with phosphoric acid gel, rinsed, and left moist; a fifth generation total etch adhesive agent (ie, Gluma Comfort Bond + Desensitizer, Heraeus Kulzer, Armonk, NY) was applied, thinned, and light-cured. A small amount of a high translucent enamel resin (ie, Venus shade, Heraeus Kulzer, Armonk, NY) was applied to the index in the site of the fractured area and then seated in the patient’s mouth. Once seated, excess resin was removed and the lingual shelf was shaped using a composite instrument (Figure 5). The author’s objective was to keep the layer as thin as possible and to use the lingual embrasure and incisal edge of the index as a guide to establish the lingual plane. By selecting a translucent shade of resin, this layer would not influence the opaque, body, and enamel shades that would be applied subsequently. Once this layer was established, it was light cured and the index was removed (Figure 6).

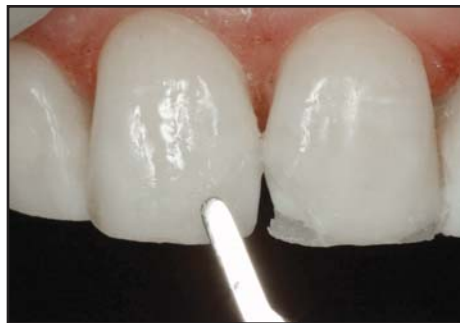In this Class IV case, it was important to conceal the “transition line” or junction between the natural tooth structure and the various opacities of composite materials.



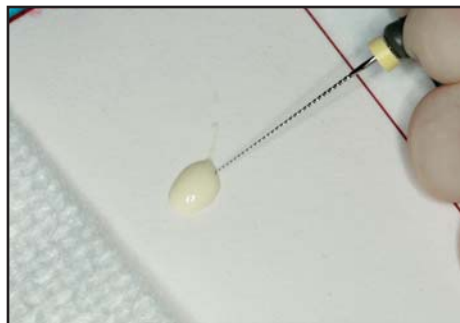
**Figure 7.** An opaque layer (A20) was placed on the mesial-lingual aspect of the fracture line.



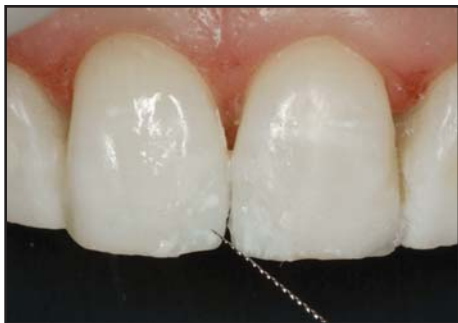**Figure 8.** A body shade layer was applied which, again, was kept away from the facial plane to allow for the enamel layer.



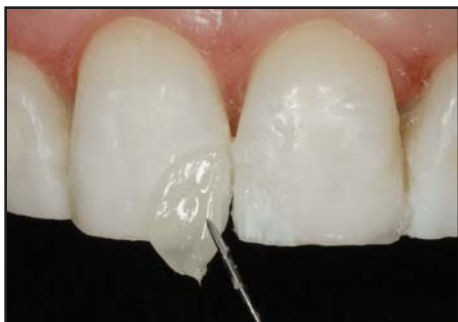**Figure 9.** Removal of excess resin to preserve the beveled space for the final enamel layer.



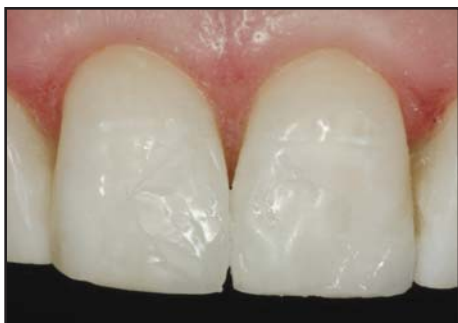**Figure 10.** To replicate color characteristics of the natural dentition, tints were prepared for application using a #8 endodontic file.



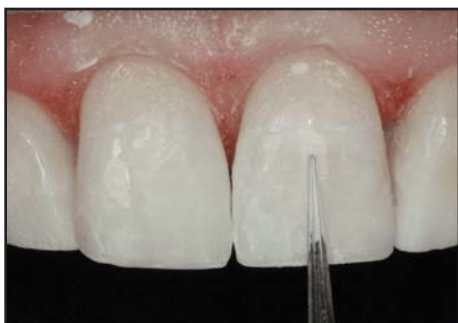**Figure 11.** Color characteristics were applied using a #8 endodontic file.



**Figure 12.** Application of the highly translucent enamel layer.



**Figure 13.** Sculpting of the enamel layer over the beveled facial aspect.



**Figure 14.** Surface texture was created with the use of finishing burs prior to polishing with finishing disks.

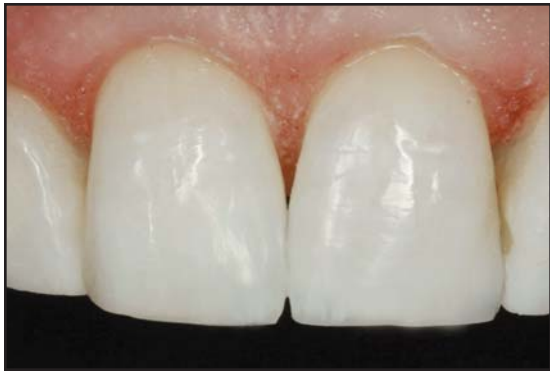While some clinicians recommend the use of opacious dentin shades that are one to two shades darker than the final target shade,<sup>9</sup> the author prefers to use dentin shades with the same basic shade as the overlying enamel layers and the final overall shade. One must always remember that if this deeper dentinal layer is placed thicker than necessary, it could be inadvertently exposed during the finishing process, allowing its color to show through on the surface of the restoration. This could potentially lead to an unacceptable aesthetic result if the underlying layer is noticeably darker than the enamel/body layer. Whereas, if the basic shades are the same, it will not compromise the aesthetics.

The opacious dentin (OA2) microhybrid resin (ie, Venus, Heraeus Kulzer, Armonk, NY) was applied and adapted to the transition zone of both restorations (Figure 7). This layer was then blended along the fracture line but kept well shy of the facial plane. Space had to be left for both a semitranslucent enamel (body) shade and a high translucent (enamel) shade on top of this layer. Once adapted, the dentin layer was light cured into place.

The third layer, a semitranslucent enamel/body shade (Venus A2), was then applied (Figure 8). This layer was adapted to contour but kept approximately 0.5 mm shy of the final facial plane in order to provide space for the final high translucent enamel shade (Figure 9). Since vertical streaks and spotted areas of hypocalcified tints were identified in the preoperative assessment of the remaining natural tooth, small grooves or "receptacles" were created to receive the tints that would replicate the natural characterizations of the teeth. This layer was then light cured. Tints were applied with a #8 endodontic file, which was used to create "spots" as required to achieve natural aesthetics (Figures 10 and 11). Once the tints were applied as desired, they were light cured.

The fourth and final layer to be applied was the highly translucent enamel resin (ie, Venus shade T2, Heraeus Kulzer, Armonk, NY). It was built up in a very thin layer, slightly beyond the facial plane of the teeth (Figure 12). The enamel layer was sculpted onto the long, undulating bevel, contoured with a sable brush, and light cured (Figure 13).

Final contouring was accomplished with a series of fine diamonds and fluted carbide finishing burs (Jeff T. Blank, DMD, Composite Preparation and Finishing Bur



**Figure 15.** Note the seamless transition from natural tooth to resin material along the fracture line, the incorporation of the tints, and the overall shade and value match.

Block, Axis Dental, Irvine, TX) (Figure 14). A series of polishing discs and strips were used to render the definitive polish for the restorations (Figure 15).

### Discussion

The author prefers to apply tints with a #8 endodontic file rather than the traditional artist brushes. The rationale behind this choice is that the file will pick up only a minimal amount of the tint material, and the file itself can be used to create spots or can be “streaked” depending on the requirements of the case. Tints should never be placed in excess, and this technique permits the novice or expert to successfully apply the appropriate amount of material on a consistent basis. Once the tints are applied as desired, they are light cured in place. If errors are made prior to curing, the tints can be wiped away with a clean sable brush and subsequently reapplied. It is important to note that color tints should always be covered with a protective layer of microhybrid or microfill resin to enhance translucent effects and to provide resistance to wear.

In the resin system demonstrated herein, three different opacities for the various shades are available, opacious dentins, semitranslucent enamels (body shades) and high translucent enamels. For the Class IV restoration, the selection of the final opacities and shades is based on the overall aesthetic appearance of the natural tooth being replicated. The clinician simply assesses the tooth clinically and, with preoperative photographs, determines which is the most dominant effect. Additionally, if errors in shade selection are evident in the previously applied layers (ie, dentin, body), the clinician has the option to

choose a final translucent layer that corrects the discrepancy. For example, if the previous built-up layers are felt to be too warm in color, this can often be offset by applying the Venus T1 (high translucent cool blue enamel) shade as the final layer. If the restoration appears to be too cool in color, then the Venus T3 shade (high translucent warm enamel) can be used to warm up the overall final shade. If the restoration looks perfect, the Venus T2 or neutral translucent is the best option.

### Conclusion

Continual refinement of composite resin chemistry has resulted in universal restoratives that can be applied to a wider range of clinical indications than could previous generations of composite. These newer formulations still require the dental professional to have a detailed understanding both of natural tooth characteristics and structures as well as the procedures used to deliver them accurately. As shown herein, translucent edge effects and maverick internal tints in particular, when carefully rendered in the buildup of composite resins, enable the clinician to instill several key subtleties that improve the aesthetics of the anterior restoration and blend the Class IV fracture harmoniously with the natural dentition.

### References

1. Buonocore MG, Davila J. Restoration of fractured anterior teeth with ultraviolet-light-polymerized bonding materials: A new technique. *J Am Dent Assoc* 1973;86(6):1349-1354.
2. Leinfelder K, Sluder T, Santos J, Wall J. Five-year clinical evaluation of anterior and posterior restorations of composite resin. *Oper Dent* 1980;5(2):57-65.
3. Fahl N Jr, Denehy GE, Jackson RD. Protocol for predictable restoration of anterior teeth with composite resins. *Pract Periodont Aesthet Dent* 1995;7(8):13-21.
4. Mopper KW. The subtleties of anterior direct-bonded Class III restorations. *Pract Periodont* 1990;2(6):17-20.
5. Baratieri LN, Coral Neto AC, Monteiro Junior S, et al. The sandwich technique, an alternative treatment for tetracycline-stained teeth: A case report. *Quintessence Int* 1991;22(12):929-933.
6. Okuda WH. Achieving optimal aesthetics for direct and indirect restorations with microhybrid composite resins. *Pract Proced Aesthet Dent* 2005;17(3):177-184.
7. Terry DA. Contemporary composite resins. In: Terry DA. *Natural Aesthetics With Composite Resin*. Mahwah, NJ: Montage Media Corporation, 2004:20-37.
8. Koczarski MJ. Achieving natural aesthetics with direct resin composites: Predictable clinical protocol. *Pract Proced Aesthet Dent* 2005;17(8):523-525.
9. Fahl N Jr. Predictable aesthetic reconstruction of fractured anterior teeth with composite resins: A case report. *Pract Periodont Aesthet Dent* 1996;8(1):17-31.
10. Jackson RD. Understanding the characteristics of naturally shaded composite resins. *Pract Proced Aesthet Dent* 2003;15(8):577-585.
11. Terry DA. Enhanced resilience and esthetics in a Class IV restoration. *Compend Contin Educ Dent Suppl* 2000;21(26):19-25.
12. Terry DA, Leinfelder KF. An integration of composite resin with natural tooth structure: The class IV restoration. *Pract Proced Aesthet Dent* 2004;16(3):235-242.